

CLINICAL INVESTIGATION

Head and Neck

INTRAOPERATIVE RADIATION THERAPY FOR RECURRENT
HEAD-AND-NECK CANCER: THE UCSF EXPERIENCE

ALLEN M. CHEN, M.D.,* M. KARA BUCCI, M.D.,* MARK I. SINGER, M.D.,† JOAQUIN GARCIA, M.D.,‡
MICHAEL J. KAPLAN, M.D.,§ ALBERT S. CHAN, C.M.D., R.T.T.,* AND THEODORE L. PHILLIPS, M.D.*

Departments of *Radiation Oncology, †Otolaryngology, Head and Neck Surgery, and ‡Pathology, University of California, San Francisco, Comprehensive Cancer Center, San Francisco, CA; §Department of Otolaryngology, Head and Neck Surgery, Stanford University School of Medicine, Stanford, CA

Purpose: To review a single-institutional experience with the use of intraoperative radiation therapy (IORT) for recurrent head-and-neck cancer.

Methods and Materials: Between 1991 and 2004, 137 patients were treated with gross total resection and IORT for recurrence or persistence of locoregional cancer of the head and neck. One hundred and thirteen patients (83%) had previously received external beam radiation as a component of definitive therapy. Ninety-four patients (69%) had squamous cell histology. Final surgical margins were microscopically positive in 56 patients (41%). IORT was delivered using either a modified linear accelerator or a mobile electron unit and was administered as a single fraction to a median dose of 15 Gy (range, 10–18 Gy). Median follow-up among surviving patients was 41 months (range, 3–122 months).

Results: The 1-year, 2-year, and 3-year estimates of in-field control after salvage surgery and IORT were 70%, 64%, and 61%, respectively. Positive margins at the time of IORT predicted for in-field failure ($p = 0.001$). The 3-year rates of locoregional control, distant metastasis-free survival, and overall survival were 51%, 46%, and 36%, respectively. There were no perioperative fatalities. Complications included wound infection (4 patients), orocutaneous fistula (2 patients), flap necrosis (1 patient), trismus (1 patient), and neuropathy (1 patient).

Conclusions: Intraoperative RT results in effective disease control with acceptable toxicity and should be considered for selected patients with recurrent or persistent cancers of the head and neck. © 2007 Elsevier Inc.

Intraoperative radiation, Head and neck, Cancer.

INTRODUCTION

Despite progress in surgical and reconstructive techniques as well as advances in radiation therapy delivery methods, a significant proportion of patients with head-and-neck cancer develop locoregional recurrence or experience disease persistence after completion of definitive therapy (1–4). Although the competing risk of developing distant metastasis is fairly high, up to 60% of this population will die as a direct consequence of uncontrolled tumor growth at the primary site (5). In addition, locoregional recurrences can potentially impact patient quality of life, not only serving as a source of functional impairment, but also as a morbid reminder of disease presence. Nevertheless, the optimal treatment for locally recurrent or persistent cancer of the head and neck remains to be defined, largely because of the heterogeneity of this population with respect to disease-related and patient-related factors such as previous treatment, site of tumor recurrence, disease extent, and performance status. Although surgical resection generally forms

the mainstay of treatment, effective salvage therapy is often precluded by anatomic inaccessibility, prior radiation therapy, and the risk of postsurgical complications (6). Indeed, published rates of successful surgical salvage range from 15% to 65% (7–9). Understandably, most physicians view the opportunity for salvage as a balance between the modest prospects of disease cure and preservation of quality of life.

In an attempt to improve the rate of successful salvage, we have been performing intraoperative radiation therapy (IORT) at the University of California, San Francisco (UCSF) in conjunction with salvage surgery for locally recurrent and persistent cancer of the head and neck since 1991. The advantage of IORT in this particular setting is that normal tissue surrounding the tumor bed can be manually retracted and directly shielded. This visualization allows treatment with radiation even after prior delivery of full courses of conventional external beam radiation therapy. In addition, there are purported radiobiologic advantages, which may result in enhanced tumor control (10). The

Reprint requests to: Allen M. Chen, M.D., Coastal Radiation Oncology, Inc., 100 Casa St., Suite C, San Luis Obispo, CA 93405. E-mail: allenmchen@yahoo.com

Theodore L. Phillips, M.D., is a member of the board of direc-

tors for Intraop Corporation, Santa Clara, CA.

Conflict of interest: none.

Received June 15, 2006, and in revised form Aug 16, 2006. Accepted for publication Aug 17, 2006.

purpose of this analysis is to review a long-term, single-institution experience with the use of IORT focusing on clinical outcome and safety.

METHODS AND MATERIALS

Patients

Between March 1991 and December 2004, 137 patients were treated with IORT at the time of surgery for head-and-neck cancer at UCSF. The following patients were excluded from the analysis: 23 patients treated with IORT as a component of primary surgery for cancer at the time of initial diagnosis, 8 patients treated with IORT for second or third locoregional recurrence, 4 patients with gross residual disease after subtotal resection, 3 patients who received less than the planned dose because of technical failure, and 2 patients with metastatic disease at the time of IORT. The remaining 137 patients who had gross total resection and IORT at the time of salvage surgery for histologically diagnosed recurrent or persistent head-and-neck cancer formed the primary population of this study. All patients had been previously treated with definitive therapy for their initial disease consisting of surgical resection with or without adjuvant therapy in 108 patients (79%) and external beam radiation therapy with or without chemotherapy in an additional 29 patients (21%). A total of 113 patients (83%) had previously undergone a full-course of external beam radiation therapy either in the definitive (31 patients) or postoperative (82 patients) setting. Among these patients, conventional fractionation with once-daily treatment was used in 89 patients (79%) and hyperfractionation with twice-daily treatment in 24 patients (21%). No patient had previously received interstitial radiation. The median total external beam radiation dose previously administered to the IORT site was 64 Gy (range, 45–72 Gy). Median age was 57 (range, 16–93 years). Ninety-two patients (67%) were male. Racial distribution was as follows: 72 Caucasian (53%), 30 Asian (22%), 19 Hispanic (14%), and 16 African American (12%).

The median duration from the date of primary surgery or the last date of definitive radiation therapy for initial disease to salvage surgery and IORT was 13 months (range 4–107 months) with 12 patients (9%) undergoing salvage therapy more than 5 years from initial treatment. Preoperative evaluation before salvage therapy included patient history, physical examination, and basic blood work in all patients. Axial imaging with computed tomography of the head and neck was performed in all patients as part of their workup for recurrent or persistent disease. One hundred and twelve patients (82%) had additional imaging with magnetic resonance imaging. Positron emission tomography was performed in 22 patients (16%). Informed consent for IORT was obtained in all patients at the time of consultation in the Department of Radiation Oncology before surgery.

Treatment

The technique used for delivery of IORT depended on the time of salvage treatment. Between March 1991 and December 1997, 45 patients (33%) were treated using a modified linear accelerator (Clinac 20, Varian Radiation Division, Palo Alto, CA) located in the Department of Radiation Oncology with various electron energies (6, 9, 12, 15, and 18 MeV) by means of a variety of cones made of 3-mm thick methyl methacrylate (Lucite, Plexiglas) with internal diameters ranging from 2.5 to 9.5 cm. Patients treated with this unit were transported from the operating room under general anesthesia and positioned on the radiation therapy couch immedi-

ately before the delivery of IORT. In January 1997, a specialized electron machine with mobile capability (Mobetron, Intraop, Santa Clara, CA) was installed in a dedicated operating room suite at UCSF. Beginning in December 1997, all patients receiving IORT were treated using this machine with various electron energies (4, 6, 9, and 12 MeV) by means of stainless steel cones with internal diameters ranging from 3 to 10 cm. Some had beveled ends, enabling adequate apposition of the cone to sloping surfaces in the surgical bed. Ninety-two patients (67%) were treated with the Mobetron electron IORT unit for recurrent or persistent head-and-neck cancer.

Maximal resection of all visible disease was attempted before delivery of IORT to the tumor bed through the surgical incision site. The operative procedure varied depending on the discretion of the surgeon and the type of previous surgery, with consideration given to the extensiveness, histology, and location of the recurrent tumor. Frozen sections were routinely performed intraoperatively to ensure maximum clearance of tumor. The area at highest risk for tumor recurrence was then delineated by the surgeon and radiation oncologist. The appropriate applicator and cone, selected at the discretion of the treating radiation oncologist, were then manually positioned over the target area and attached to the surgical table using a Bookwalter clamp. Gauze packing, retractors, or pliable 1–2 mm thick lead shields were used to displace or protect normal tissues near or inside the treatment field. The applicator was aligned to the linear accelerator by moving the table under the guidance of a laser docking system. Gantry rotation was performed to minimize air gaps and to reduce obliquity. Before delivery of IORT, the treatment field was suctioned to prevent any accumulated fluid or blood products from acting as a bolus. All attempts were made to isolate or shield critical nerves and vessels from the treatment field.

In general, the treatment cone was chosen so that it encompassed the target volume with a 1–2 cm margin of normal tissue. Bolus was routinely used to ensure a full surface dose. The entire target volume was encompassed with a single IORT field in 110 (80%) patients. The remaining 27 patients had more than one IORT field treated. A total of 191 fields were treated in 137 patients. The median cone size was 5 cm (range, 2.5–10 cm). The IORT dose was prescribed to the median 90% isodose line (range, 80–100%) to encompass the area at risk for microscopic disease. Electron energy was chosen on the basis of the thickness of the tumor bed taking into consideration the presence of underlying critical structures. The most commonly prescribed energy was 6 MeV, which was used in 71% of the treated fields. The median IORT dose was 15 Gy (range, 10–18 Gy) and selected at the discretion of the treating radiation oncologist. No definitive policy existed at UCSF regarding the choice of IORT dose during the span of this analysis, but 91% were treated to a dose of 15 Gy. Thirty-five patients, 11 of whom had radiation as part of their previous definitive treatment, proceeded to receive additional post-IORT external beam radiation therapy to a median dose of 54 Gy (range, 40–71 Gy) using conventional once-daily fractionation. For these patients, the median total radiation dose delivered from the time of salvage surgery was 69 Gy (range, 55–84 Gy). Ninety-nine patients (72%) subsequently received chemotherapy after salvage surgery and IORT.

Follow-up and statistical analysis

After the completion of surgery, patients were hospitalized for postsurgical monitoring. The median hospitalization time was 6

days (range, 1–11 days). Patients were asked to return to the clinic at 3-month intervals for 2 to 3 years and then yearly. Follow-up imaging was dependent on the treating physician, but in general was performed every 3 months. Patient follow-up was reported to the date last seen in clinic or to the date of death. In some cases, referring physicians were contacted to obtain information regarding patient health status. The median follow-up duration was 18 months for all patients (range, 1–122 months) and 41 months among surviving patients (range, 3–122 months).

The endpoints analyzed were overall survival, IORT in-field control, locoregional control, and distant metastasis-free survival. All events were measured from the date of salvage surgery and IORT for the locally recurrent or persistent disease. Subsequent in-field recurrence was defined as radiographic, clinical, or pathologic evidence of recurrent disease in the salvaged site treated with IORT. All other events were considered out-of-field. Regional failure was recorded separately if there was evidence of an enlarging cervical or supraclavicular mass distinct from the primary site. For patients who received IORT to two or more sites at the time of salvage surgery, an in-field recurrence was recorded if disease failure occurred at either site. All events were scored until the patient's death. The incidence and severity of complications were assessed at each follow-up visit. Actuarial rates of overall survival, IORT in-field control, locoregional control, and distant metastasis-free survival were calculated by the Kaplan-Meier method, with comparisons among groups performed with two-sided log-rank tests (11). All *p* values reported were two-sided with *p* < 0.05 used to denote statistical significance.

RESULTS

Disease characteristics

All patients had clinical, radiographic, or pathologic evidence of recurrent or persistent disease at the original tumor site or regional lymph nodes before salvage surgery and IORT. Eighty-seven patients (64%) were treated with IORT for isolated local failures, 39 patients (28%) for isolated regional failures, and 11 patients (8%) for both local and regional failures. Primary tumor sites were: 24% oropharynx; 23% oral cavity; 12% paranasal sinus; 12% parotid gland; 7% hypopharynx; 6% submandibular gland; 6% skin; 3% nasopharynx/nasal cavity; 3% larynx; 2% ear; and 2% unknown. The most common histologic subtype was squamous cell carcinoma, occurring in 94 patients (69%). Other subtypes included adenoid cystic carcinoma (18 patients), mucoepidermoid carcinoma (9 patients), adenocarcinoma (7 patients), sarcoma (4 patients), melanoma (3 patients), and acinic cell carcinoma (2 patients).

Table 1 outlines the pathologic findings of the 137 patients who underwent gross total resection at the time of salvage surgery and were treated with IORT for locally recurrent or persistent cancers of the head and neck. The median size of the recurrent tumor at the time of pathologic analysis was 2.2 cm (range, 0.0–9.5 cm). Three patients had no evidence of tumor in the resection specimen at the time of IORT, despite having positive biopsies immediately before salvage surgery. In all other patients, histology was consistent with the known primary tumor. Final surgical margins were microscopically positive in 56 patients (41%)

Table 1. Pathologic findings at the time of salvage surgery and IORT

Characteristic	<i>n</i>	%
Histology		
Squamous	94	69
Adenoid cystic	18	13
Mucoepidermoid	9	7
Adenocarcinoma	7	5
Sarcoma	4	3
Melanoma	3	2
Acinic	2	2
Tumor size (cm)		
≤2	62	45
2–4	45	33
>4	30	22
Margins		
Negative	81	59
Positive	56	41
Perineural invasion		
Yes	41	30
No	96	70
Muscle involvement		
Yes	34	25
No	103	75
Bone involvement		
Yes	16	12
No	121	88

Abbreviations: IORT = intraoperative radiation therapy; cm = centimeters.

and negative in 81 patients (59%). Perineural invasion was present in the pathology specimen at salvage surgery for 41 patients (30%). Thirty-four patients (25%) and 16 patients (12%) had pathologic evidence of muscle and bony involvement, respectively.

Overall survival

Sixty-two patients were alive at the time of this analysis. Overall survival for the entire patient population at 1, 2, and 3 years was 68%, 52%, and 36%, respectively. Patients who received IORT for recurrent or persistent disease at the primary site had significantly better survival than those who were treated with IORT for disease involving the neck. As illustrated in Fig. 1, the 3-year overall survival was 44% for patients treated at the primary site only compared with 19% for those treated at the neck (*p* = 0.001). Median survival was 20 months (range, 2–122 months) and 12 months (range, 1–51 months), respectively. None of the other clinical or disease characteristics analyzed, including age at IORT (<50 vs. ≥50 years, *p* = 0.34), initial treatment modality (surgery vs. radiation therapy, *p* = 0.74), time interval from primary treatment to IORT (≤12 months vs. >12 months, *p* = 0.11), histology (squamous vs. nonsquamous cell carcinoma, *p* = 0.09), pathologic tumor size at salvage (≤2 cm vs. >2 cm, *p* = 0.14), margin status (*p* = 0.17), perineural invasion (*p* = 0.23), muscle involvement (*p* = 0.42), bony invasion (*p* = 0.21), use of external beam radiation after IORT (*p* = 0.84), and IORT delivery method

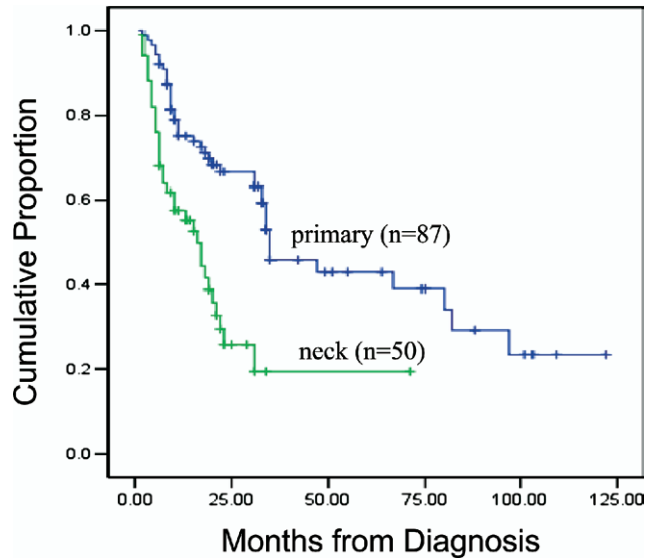


Fig. 1. Overall survival for all patients treated with intraoperative radiation therapy according to treatment site (primary vs. neck).

(modified linear accelerator vs. mobile electron unit, $p = 0.55$) was predictive of overall survival.

IORT in-field control

Thirty-five patients experienced a subsequent recurrence at the operative site after completion of salvage surgery and IORT, 19 of which were isolated first events. Twenty-three of the in-field recurrences (66%) were biopsy-proven, with the remaining 12 recurrences (34%) classified based on clinical or radiographic findings. The median time to second recurrence after IORT was 6 months (range, 1–54 months), with 28 in-field recurrences occurring within 1 year from the time of IORT. For the entire patient population, the 1-year, 2-year, and 3-year estimates of in-field control were 76%, 69%, and 67%, respectively. In-field control after salvage surgery and IORT is illustrated in Fig. 2.

The only parameter predictive of in-field recurrence was positive microscopic margins at the time of salvage surgery and IORT. As depicted in Fig. 3, the 1-year, 2-year, and 3-year rates of IORT in-field control were 87%, 82%, and 82%, respectively, for patients treated with negative surgical margins compared to 65%, 53%, and 48%, respectively, for those with positive margins ($p = 0.002$). None of the remaining parameters analyzed, including age at diagnosis, initial treatment modality, time from primary treatment to IORT, site of IORT, histology, pathologic tumor size, perineural invasion, muscle involvement, bony invasion, and use of post-IORT external beam radiation was predictive of in-field control ($p > 0.05$, for all). The 3-year rate of in-field control for patients treated with the linear accelerator was 64% compared with 69% for patients who underwent IORT with the mobile electron unit ($p = 0.39$).

Locoregional control

Among the 87 patients who underwent IORT to disease at the primary site, 15 patients developed regional recurrences

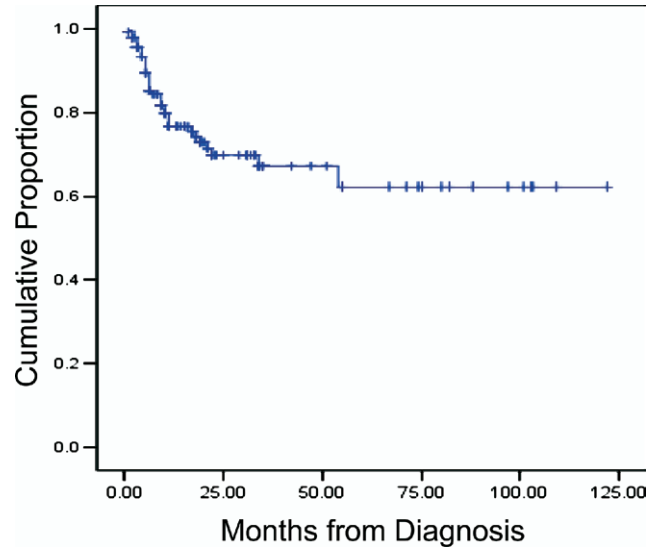


Fig. 2. Intraoperative radiation therapy in-field control for the entire patient population.

at out-of-field sites at a median of 10 months (range, 3–74 months) after completion of salvage therapy. Nine of these were isolated recurrences, and the remaining 6 recurrences occurred concurrently or subsequent to the development of distant metastases. Among the 50 patients who received IORT to disease sites in the neck, 15 experienced a subsequent second recurrence at the treated site at a median of 3 months (range, 1–20 months) after salvage therapy. Six of these were isolated recurrences, and two occurred concurrently or subsequent to the development of disease failure at the primary site. The remaining seven recurrences occurred concurrently or subsequent to the development of distant metastases. As illustrated in Fig. 4, the 1-year, 2-year, and 3-year estimates of locoregional control for the entire patient population were 68%, 61%, and 51%, respectively.

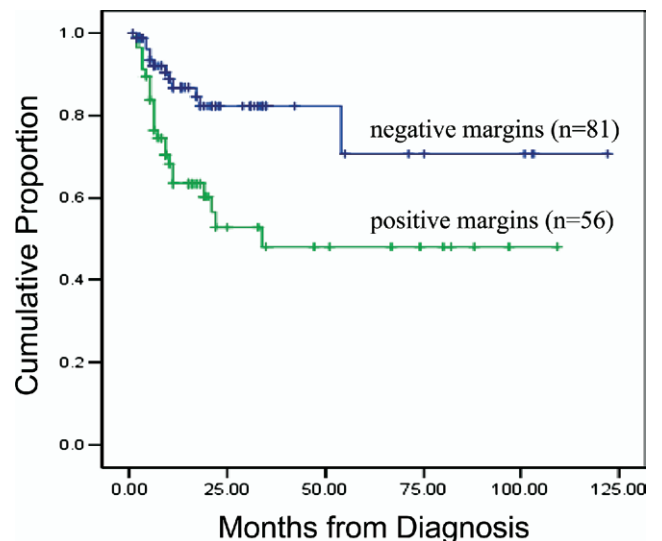


Fig. 3. Intraoperative radiation therapy (IORT) in-field control for all patients treated with IORT according to surgical margin status.

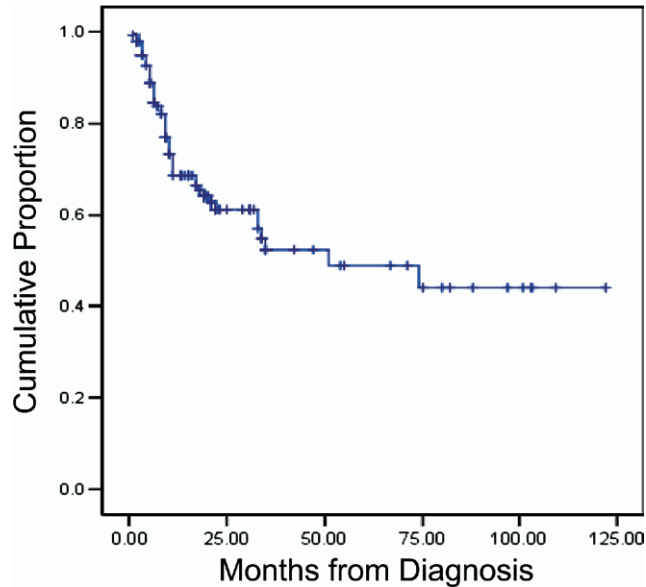


Fig. 4. Locoregional control for the entire patient population.

Distant metastases

As shown in Fig. 5, the 1-year, 2-year, and 3-year distant metastasis-free survival rates were 78%, 67%, and 46%. Patients treated with IORT to the primary tumor site had a 3-year distant metastasis-free survival of 61% compared with 30% for those who were treated with IORT to disease sites in the neck ($p = 0.001$). None of the other clinical or disease characteristics analyzed, including age, initial treatment modality, time from primary treatment to IORT, histology, pathologic tumor size, margin status, perineural invasion, muscle involvement, bony invasion, use of post-IORT external beam radiation, and IORT delivery method was predictive of distant metastasis-free survival ($p > 0.05$, for all).

Complications

There were no perioperative fatalities. Four patients had superficial wound infections without tissue breakdown requiring intravenous antibiotics during the immediate postoperative period. Two patients, both of whom received IORT doses of 15 Gy for locally recurrent cancers of the oral cavity, developed orocutaneous fistulas at approximately 1 and 3 months after salvage surgery that required subsequent surgical reconstruction. Both of these patients were previously treated for primary squamous cell carcinoma involving the hard palate with surgery and postoperative radiation therapy to doses of 54 Gy and 60 Gy, respectively. Neither received post-IORT radiation therapy. Another patient, treated with an IORT dose of 15 Gy for recurrent squamous cell carcinoma of the base of tongue after previously undergoing surgery with postoperative radiation therapy to 60 Gy, experienced wound dehiscence with flap necrosis requiring surgical debridement. An additional patient, treated with an IORT dose of 15 Gy for recurrent mucoepidermoid carcinoma of the parotid gland

initially managed with surgery alone, developed trismus 4 months after completion of IORT that resolved over the course of 1 year with occupational therapy. Last, 1 patient treated with an IORT dose of 15 Gy for adenoid cystic carcinoma of the submandibular gland, initially managed with surgery and postoperative radiation to a dose of 64 Gy, developed sudden-onset facial pain secondary to neuropathy at approximately 1 month after salvage treatment. This patient's symptom was managed medically with narcotics and gradually resolved over the course of 2 years. No patient developed clinical evidence of osteoradionecrosis, bone fracture, brain necrosis, or carotid artery hemorrhage.

DISCUSSION

Prognosis after recurrence or persistence of locoregional disease after completion of definitive therapy for head-and-neck cancer is relatively poor, but varies based on such factors as histology, tumor site, disease extent, and performance status (12–15). Depending on the specific selection criteria used, the proportion of patients eligible for salvage surgery after experiencing recurrent or persistent locoregional disease ranges from 34% to 75% (16–18). However, even among patients with seemingly resectable lesions, surgery can be technically challenging due to the difficulties of operating in previously manipulated or irradiated tissue as well as the proximity of tumor to critical structures such as the carotid artery, skull base, esophagus, and trachea. Moreover, the low cure rates associated with surgical salvage have led some authors to question whether the modest benefits outweigh the potentially increased morbidity (19, 20). Similarly, salvage therapy using reirradiation is controversial. In a large study of 169 patients, De Crevoisier demonstrated that full-dose reirradiation of head-and-neck sites resulted in unacceptably high rates of late toxicity, including mucosal necrosis in 21%, osteoradionecrosis in

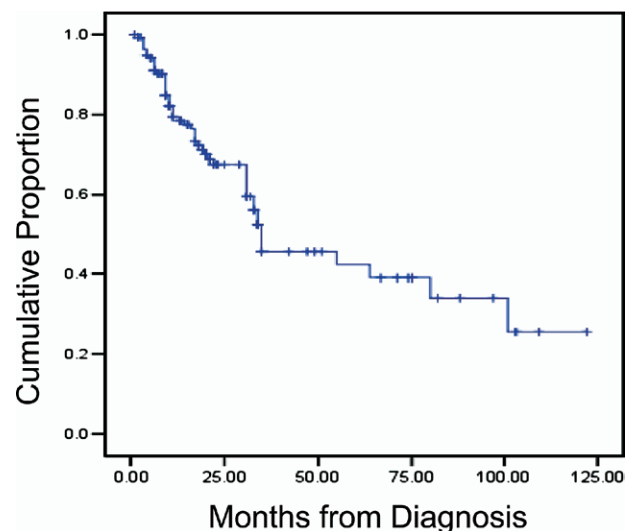


Fig. 5. Distant metastasis-free survival for the entire patient population.

8%, and 5 deaths from carotid hemorrhage (21). Although the results of more recent studies analyzing reirradiation using altered fractionation and brachytherapy have been somewhat more promising, the role of reirradiation after previous full-course radiation remains investigational (22–25).

The primary advantage of IORT is that it can deliver a high dose of radiation therapy to microscopic disease while minimizing the risk of reirradiation to dose-limiting normal tissue. By enhancing local control without increasing toxicity, this approach may theoretically lead to an improvement in the therapeutic ratio. Encouraging results from Phase III trials involving the pancreas, stomach, and retroperitoneum have led investigators to hypothesize that this technique may be of considerable utility for other sites where tumor infiltration may make complete resection difficult, such as the head and neck (26–28). This present series demonstrates that although long-term survival is relatively limited for patients who present in this setting, effective disease control can be obtained with this multimodality approach in appropriately selected patients.

The results of our analysis compare favorably with those from other single-institutional experiences. Rate *et al.* demonstrated a 2-year local control rate of 61% among 47 patients treated with IORT for recurrent head-and-neck cancer (29). However, Nag *et al.* reported a 2-year local control rate of only 13% among 38 patients treated with IORT for recurrent head-and-neck cancer (30). Most recently, Pinheiro *et al.* reported 5-year in-field control rates of 41% and 52% for 34 patients with squamous cell carcinoma and 10 with nonsquamous cell carcinoma of the head and neck, respectively, treated with IORT at the Mayo Clinic (31). Patient selection criteria and heterogeneity with respect to disease characteristics are most likely the major factors responsible for the wide variation in published rates of disease control. For instance, patients with laryngeal cancers are more amenable to successful salvage therapy compared with tumors arising from other sites, and patients presenting with neck recurrences generally have a worse prognosis than those with recurrences at the primary site (18). Similarly, those who present with a first local recurrence have a better prognosis than those who are treated for a second or third recurrence. Imbalances in clinical parameters such as performance status, weight loss, and the extensiveness of presalvage workup between series could also lead to conflicting results between series.

Differences in therapeutic approaches and technique may have also contributed to the observed discrepancies in outcome. Studies reporting poorer local control often included patients with gross residual disease after surgery or who were treated with palliative intent (29–32). It is particularly notable that the vast majority of centers reporting on their experiences with IORT for recurrent head-and-neck cancer only considered its use for “high-risk” patients with positive or close margins after salvage surgery. Indeed, the proportion of patients treated with positive margins was unspecified in some series and was as high as 100% in others (29–33). This is in contrast to the present series in which

only 41% of the patients were treated with positive microscopic margins and none with gross disease. Moreover, there are no studies, to our knowledge, that have analyzed the effect of IORT dose on local control, although some authors have speculated that higher doses may be required in the presence of microscopic residual disease (30). Similarly, some authors suggest that the addition of adjuvant external beam radiation therapy or chemotherapy after salvage surgery and IORT in selected patients may enhance local control, although we were unable to detect any statistically significant benefit in the relatively small number of patients treated in this manner in our series (10). Last, variations in the methods of reporting clinical outcomes with IORT must be considered in interpreting results and drawing conclusions. Although most reports have defined local control as in-field control within the IORT port, others included both failures within and outside the IORT port in determining local control (29–34).

A limitation of this report was that as a result of its retrospective nature, we were unable to differentiate between true recurrent cancers and new primary tumors of the head and neck among the patients undergoing salvage therapy. This may have been relevant because patients presenting with the latter tend to have improved prognosis compared with those with the former. Based on the concept of “field cancerization” originally proposed by Slaughter *et al.* in 1953, it is well known that patients who experience and survive head-and-neck cancer are at an elevated risk for developing a second primary tumor in the same anatomic field during the ensuing years (35). That the overwhelming majority of patients (91%) in the present series were treated with salvage surgery and IORT more than 5 years after initial treatment for their primary head-and-neck cancers suggest, however, that the incidence of second primary tumors in our population was low.

Although several studies have established that the role of IORT in the setting of gross residual disease is extremely limited because of the exceedingly high rates of local recurrence, the significance of microscopically positive margins has been somewhat controversial, both for the treatment of head-and-neck cancers and for disease at other sites (10). Similar to other series, we were able to demonstrate a statistically significant difference in local control between patients treated with negative and positive microscopic margins with IORT. Toita *et al.* also reported significantly improved in-field control rates of 82% and 55% for close and positive margins, respectively, which translated into a significantly improved overall survival (36). Garrett *et al.* treated 28 patients with advanced or recurrent squamous cell carcinoma and reported local control rates of 87% for close margins and 75% for microscopic margins (37). Most recently, Schleicher *et al.* showed that rates of local recurrence were 60% and 50% for patients treated with microscopically positive and negative margins, respectively (38). Although patients with positive microscopic margins but without gross disease after salvage resection can be successfully treated with IORT, our findings strongly suggest that

negative margins should be attained to ensure favorable results.

The relatively low rate of observed complications with long follow-up is particularly reassuring. In contrast, Haller *et al.* demonstrated a major complication rate of 16%, including wound infections, cerebrospinal fluid leak, and fistula, among 53 patients who underwent IORT in conjunction with surgery for advanced head-and-neck cancer (39). Similarly, Toita reported a 2-year complication rate of 32.8% among 25 patients treated with IORT including 5 patients with osteoradionecrosis and 3 with carotid artery hemorrhage (36). The variation in observed complication rates can likely be accounted for by differences in IORT dose. Studies reporting high incidence of complications routinely used higher doses compared with the 15 Gy used at our institution. For instance, Freeman *et al.* reported 3 cases of osteoradionecrosis in 3 patients who received IORT doses of 100 Gy, 50 Gy, and 20 Gy, respectively (34). Because of the limited IORT dose range employed in the present series, we were unable to evaluate the effect of dose on clinical outcome or complications. Differences in prescription points may have also contributed to observed discrepancies in complications. Some groups routinely prescribe to maximum depth without accounting for individual patient anatomy. It is worth noting that at our institution, IORT is sometimes aborted if patient anatomy prevents delivery of a uniform dose to tumor bed. Furthermore, it is important to recognize that all of the observed complica-

tions cannot be clearly attributed to IORT because the surgical complication rate for salvage surgery is high, especially in previously irradiated tissue, even when IORT is not used.

Although randomized data are lacking and comparisons of observed outcomes after salvage surgery with or without IORT for head-and-neck cancer among retrospective series are limited by the heterogeneity of patient populations, our results compare favorably to historical controls. Goodwin published a meta-analysis of 12 studies and reported a 5-year overall survival rate of 36% for patients treated with surgery alone for locally recurrent head-and-neck cancer (18). However, eligibility criteria for surgical resection for recurrent or persistent disease vary between institutions, and it is important to note that reported outcomes are confounded by selection criteria inherent in these studies. At our institution, treatment decisions are typically made with multidisciplinary input, considering disease control, quality of life, and cosmetic factors. Even so, surgical criteria and operative approaches lack uniformity and continue to vary based on physician preferences. In conclusion, our results, spanning 15 years, demonstrate that although overall survival after recurrence or persistence of locoregional head-and-neck cancer after definitive therapy is relatively limited, effective disease control, with acceptable side effects, can be achieved in appropriately selected patients using salvage surgery and IORT.

REFERENCES

- Vokes EE, Weichselbaum RR, Lippman EM, *et al.* Head and neck cancer. *N Engl J Med* 1993;328:184–194.
- Taneja C, Allen H, Konecny RJ, *et al.* Changing patterns of failure of head and neck cancer. *Arch Otolaryngol Head Neck Surg* 2002;128:324–327.
- Fu KK, Pajak TF, Trotti A, *et al.* A Radiation Therapy Oncology Group (RTOG) phase III randomized study to compare hyperfractionation and two variants of accelerated fractionation to standard fractionation radiotherapy for head and neck squamous cell carcinomas: First report of RTOG 9003. *Int J Radiat Oncol Biol Phys* 2000;48:7–16.
- Calais G, Alfonsi M, Bardet E, *et al.* Randomized trial of radiation therapy versus concomitant chemotherapy and radiation therapy for advanced-stage oropharynx carcinoma. *J Nat Cancer Inst* 1999;91:2081–2086.
- Honk WK, Bromer RH, Amato DA, *et al.* Patterns of relapse in locally advanced head and neck cancer patients who achieved complete remission after combined modality treatment. *Cancer* 1985;45:1242–1245.
- Ridge JA. Squamous cancer of the head and neck: Surgical treatment of local and regional recurrences. *Semin Oncol* 1993;20:419–429.
- Schwartz GJ, Mehta RH, Wenig BL, *et al.* Salvage treatment for recurrent squamous cell carcinoma of the oral cavity. *Head Neck* 2000;22:34–41.
- Gleich LL, Ryzenman J, Gluckman JL, *et al.* Recurrent advanced (T3 or T4) head and neck squamous cell carcinoma. *Arch Otolaryngol Head Neck Surg* 2004;130:35–38.
- Jones KR, Lodge-Rigal RD, Reddick RL, *et al.* Prognostic factors in the recurrence of stage I and II squamous cell cancer of the oral cavity. *Arch Otolaryngol Head Neck Surg* 1992;118:483–485.
- Carter YM, Jablons DM, DuBois JB, *et al.* Intraoperative radiation therapy in the multimodality approach to upper aerodigestive tract cancer. *Surg Oncol Clin N Am* 2003;12:1043–1063.
- Kaplan EL, Meier P. Nonparametric estimation from incomplete observations. *J Am Stat Assoc* 1958;53:547–581.
- Davidson J, Keane T, Brown D, *et al.* Surgical salvage after radiotherapy for advanced laryngopharyngeal carcinoma. *Arch Otolaryngol Head Neck Surg* 1997;123:420–424.
- Marcial VA, Hanley JA, Ydrach A, *et al.* Tolerance of surgery after radical radiotherapy of carcinoma of the oropharynx. *Cancer* 190;46:1910–1912.
- Parsons JT, Mendenhall WM, Stringer SP, *et al.* Salvage surgery following radiation failure in squamous cell carcinoma of the supraglottic larynx. *Int J Radiat Oncol Biol Phys* 1995;32:605–609.
- Argiris A, Li Y, Forastiere A. Prognostic factors and long-term survivorship in patients with recurrent or metastatic carcinoma of the head and neck. *Cancer* 2004;101:2222–2229.
- Taussky D, Dulguerov P, Allal AS. Salvage surgery after radical accelerated radiotherapy with concomitant boost technique for head and neck carcinomas. *Head Neck* 2005;27:182–186.
- Wong LY, Wei WI, Lam LK, *et al.* Salvage of recurrent head and neck squamous cell carcinoma after primary curative surgery. *Head Neck* 2003;25:953–959.
- Goodwin WJ. Salvage surgery for patients with recurrent squamous cell carcinoma of the upper aerodigestive tract:

- when do the ends justify the means? *Laryngoscope* 2000; 110(Suppl 93):1–18.
19. Arnold DJ, Goodwin WJ, Weed DT, *et al.* Treatment of recurrent and advanced stage squamous cell carcinoma of the head and neck. *Semin Radiat Oncol* 2004;14:190–195.
 20. De Crevoisier R, Domenge C, Wibault P, *et al.* Full-dose reirradiation for unresectable head and neck carcinoma: Experience at the Gustave-Roussy Institute in a series of 169 patients. *J Clin Oncol* 1998;16:3556–3562.
 21. Machtay M, Rosenthal DI, Chalian AA, *et al.* Pilot study of postoperative reirradiation, chemotherapy, and amifostine after surgical salvage for recurrent head-and-neck cancer. *Int J Radiat Oncol Biol Phys* 2004;59:72–77.
 22. Puthawala A, Syed AM, Gamie S, *et al.* Interstitial low-dose-rate brachytherapy as a salvage treatment for recurrent head-and-neck cancers: Long-term results. *Int J Radiat Oncol Biol Phys* 2001;51:354–362.
 23. Hepel JT, Syed AM, Puthawala A, *et al.* Salvage high-dose rate (HDR) brachytherapy for recurrent head-and-neck cancer. *Int J Radiat Oncol Biol Phys* 2005;62:1444–1450.
 24. Milano MT, Vokes EE, Salama JK, Stenson KM, *et al.* Twice-daily reirradiation for recurrent and second primary head-and-neck cancer with gemcitabine, paclitaxel, and 5-fluorouracil chemotherapy. *Int J Radiat Oncol Biol Phys* 2005;61:1096–1106.
 25. Zelefsky MJ, Zimberg SH, Raben A, *et al.* Brachytherapy for locally advanced and recurrent lymph node metastases. *J Brachytherapy Int* 1998;14:123–130.
 26. Sindelar WF, Kinsella WT. Randomized trial of intraoperative radiotherapy in unresectable carcinoma of the pancreas. *Int J Radiat Oncol Biol Phys* 1986;12:148.
 27. Sindelar WF, Kinsella TJ, Tepper JE. Randomized trial of intraoperative radiotherapy in locally advanced gastric cancer. *Proc Am Soc Clin Oncol* 1987;6:91.
 28. Sindelar WF, Kinsella TJ, Chen PW, *et al.* Intraoperative radiotherapy in retroperitoneal soft tissue sarcomas. Final results of a prospective randomized clinical trial. *Arch Surg* 1993;128:402.
 29. Rate WR, Garrett P, Hamaker R, *et al.* Intraoperative radiation therapy for recurrent head and neck cancer. *Cancer* 1991;67:2738–2740.
 30. Nag S, Schuller DE, Martinez-Monge R, *et al.* Intraoperative electron beam radiotherapy for previously irradiated advanced head and neck malignancies. *Int J Radiat Oncol Biol Phys* 1998;42:1085–1089.
 31. Pinheiro AD, Foote RL, McCaffrey TV, *et al.* Intraoperative radiotherapy for head and neck skull base cancer. *Head Neck* 2002;25:217–226.
 32. Spaeth J, Andreopoulos D, Unger T, *et al.* Intraoperative radiotherapy—5 years of experience in the palliative treatment of recurrent and advanced head and neck cancers. *Oncology* 1997;54:208–213.
 33. Vikram B, Strong EW, Shah JP, *et al.* Intraoperative radiotherapy in patients with recurrent head and neck cancer. *Am J Surg* 1985;150:485–487.
 34. Freeman SB, Hamaker RC, Singer MI, *et al.* Intraoperative radiotherapy of head and neck cancer. *Arch Otolaryngol Head Neck Surg* 1990;116:165–168.
 35. Slaughter DP, Southwick HW, Smejkal W. “Field cancerization” in oral stratified squamous epithelium: Clinical implications of multicentric origin. *Cancer* 1953;6:963–968.
 36. Toita T, Nakano M, Takizawa Y, *et al.* Intraoperative radiation therapy for head and neck cancer. *Int J Radiat Oncol Biol Phys* 1994;30:1219–1224.
 37. Garrett P, Pugh N, Ross D, *et al.* Intraoperative radiation therapy for advanced or recurrent head and neck cancer. *Int J Radiat Oncol Biol Phys* 1987;13:785–788.
 38. Schleicher UM, Phonias C, Spaeth J, *et al.* Intraoperative radiotherapy for pre-irradiated head and neck cancer. *Radiother Oncol* 2001;58:77–81.
 39. Haller JR, Mountain RE, Schuller DE, *et al.* Mortality and morbidity with intraoperative radiotherapy for head and neck cancer. *Am J Otolaryngol* 1996;17:308–310.